

Vidange
Ventricules


Faux du Cerveau
Tente

PERSON



HeyPyss
17/12/11

Whiplash



Th₂ rotation droite

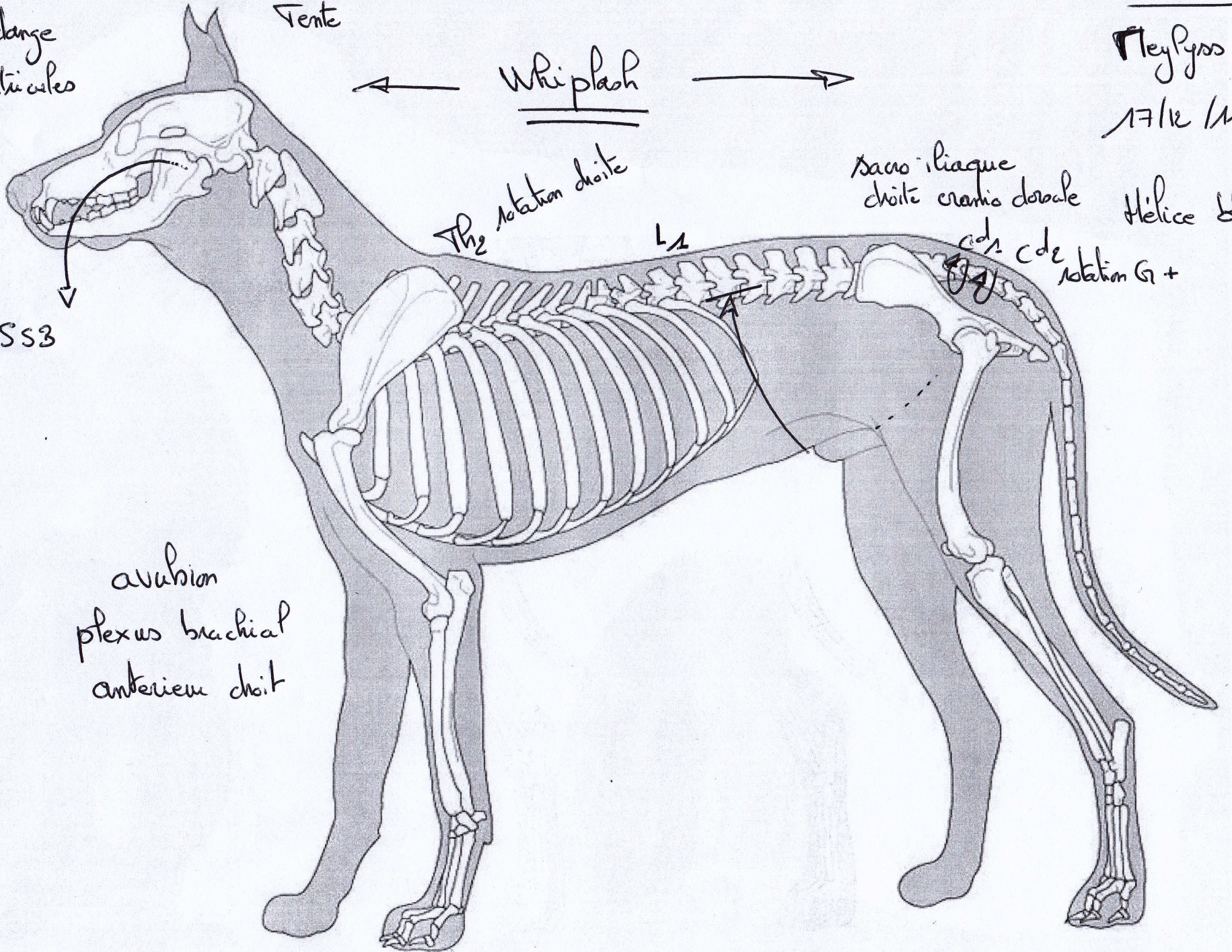
sacro-iliaque
droite cranio dorsale

Helice bloquée

C₇ C₆ rotation G +

S53

avulsion
plexus brachial
anterior droit



Chien Cyst. Furet on [sb]in